

## Auto-immune gastritis induced by pembrolizumab, an anti-PD-1, in a melanoma patient

J. Vandepapelière<sup>1</sup>, J. Sipler<sup>2</sup>, L. Libbrecht<sup>3</sup>, H. Dano<sup>3</sup>, J-F. Baurain<sup>1</sup>, T. Moreels<sup>2</sup>

(1) Division of Oncology, Cliniques Universitaires Saint Luc, Université catholique de Louvain, Brussels, Belgium ; (2) Division of Gastroenterology, Cliniques Universitaires Saint Luc, Université catholique de Louvain, Brussels, Belgium ; (3) Division of Anatomopathology, Cliniques Universitaires Saint Luc, Université catholique de Louvain, Brussels, Belgium.

### Abstract

We report a case of a 67-years-old woman presenting a severe acute lymphocytic gastritis induced by pembrolizumab, an immune checkpoint inhibitor (ICI). This gastritis was her third auto-immune adverse event after 5 years of treatment with pembrolizumab, it was metabolically active at the PET Scan and confirmed by analysis of the gastric biopsies. Pembrolizumab treatment cessation and high doses of corticosteroids completely normalized the stomach clinically, endoscopically and histologically. This patient was in complete remission of her metastatic melanoma. Therefore, pembrolizumab therapy was not restarted and the patient is still in remission 6 months later. This strategy is supported by recent publications describing a relapse rate inferior to 10% in patients in complete remission after 2 years of immunotherapy.

Particularities of this case are: rareness of this adverse event, late onset after introduction of pembrolizumab, evocative PET scan image, specific endoscopic aspect and histology. In addition, the favorable oncologic evolution of the patient after treatment cessation confirms the prolonged remission after immunotherapy. (*Acta gastroenterol. belg.*, 2020, 83, 482-484).

**Key words** : melanoma, immune checkpoint inhibitor, acute gastritis.

### Introduction

Immune checkpoint inhibitors (ICI), such as anti-PD-1, restore the function of exhausted T cells and boost the anti-tumoral immune response. They represent a major breakthrough in the oncology field. In metastatic melanoma, the median survival reaches 38 months when anti-PD1 are given as first-line treatment irrespective of BRAF status. Another major benefit is the possibility of extended responses (1).

ICI are usually well tolerated with a minority of the patients presenting severe reactions. If they are identified at an early stage and adequately managed, they do not negatively impact the patient's prognosis (3). The mechanisms responsible of the adverse reactions are numerous and not yet all identified. Most of the side effects are cutaneous, hepatic, colic, pulmonary or endocrine. They are rarely encountered in the upper gastrointestinal tract and are more frequent and severe with anti-CTLA-4 than with anti-PD-1, with a grade 3 AEs rate of 20% vs 11-15% respectively(3). The general therapeutic algorithm lies on the toxicity gradation : grade 1 toxicity, treatment is maintained, with symptomatic therapy; grade 2, interruption of immunotherapy until decrease of severity to grade 1 ; grade 3, or persistent grade 2, high dose corticotherapy is initiated with interruption

of immunotherapy. In patients with resistance to corticotherapy, stronger immunosuppression is needed.

### Case report

We present a 67-years-old female patient with a melanoma on her left hip, stage IIA, operated in July 2010. In May 2011, she relapsed with an in-transit metastasis on the posterior thigh together with subcutaneous nodules. Systemic treatment with experimental vaccinothérapie was initiated. In November 2012, a new in-transit metastasis was resected on her leg. Ipilimumab therapy, an anti-CTLA4 ICI, was initiated but the patient developed an auto-immune colitis after 4 injections. In August 2013, she developed acute interstitial nephritis with renal insufficiency while under high doses of corticoids. Renal function normalized under tapering of corticosteroid treatment. Because of disease progression, nivolumab was proposed in a clinical trial.

Despite this therapy, disease progression occurred with pulmonary and hepatic metastases, a colic lesion

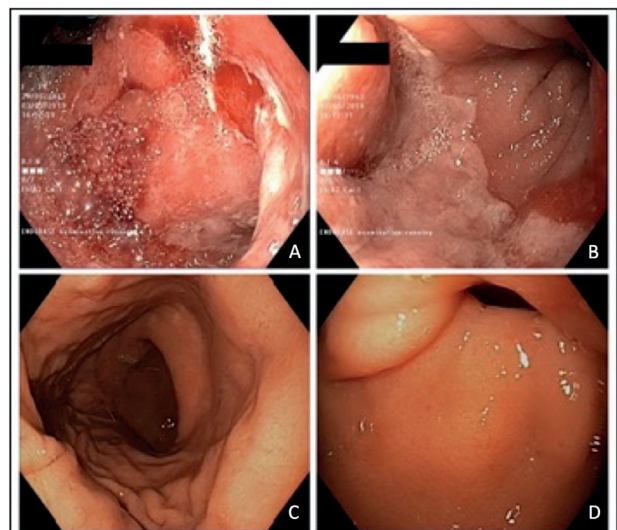


Fig. 1. — Endoscopy.

A,B : before corticotherapy ; C,D : after corticotherapy

Correspondence to : Julie Vandepapelière 70 rue René Delory, 5001 Belgrade Belgium.

E-mail : julie.vandepapeliere@gmail.com

Submission date : 03/03/2020

Acceptance date : 07/03/2020

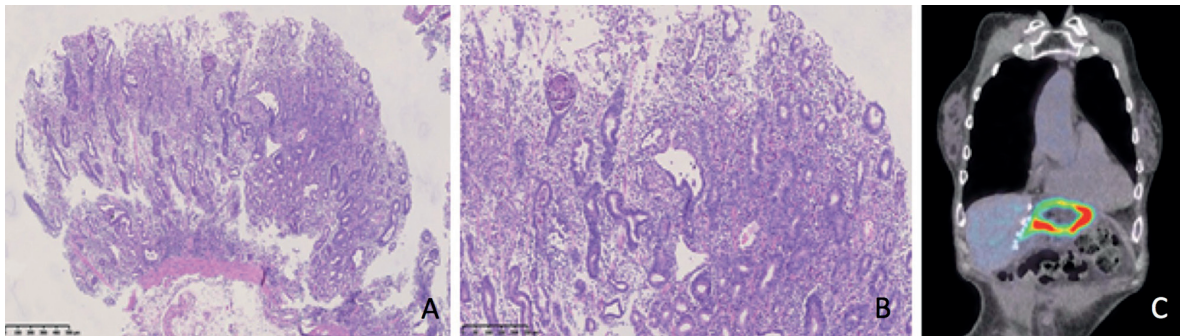


Fig. 2. — Histologic findings (A,B), Pet CT (C).

A : glandular atrophy ; B. regenerative aspect of the mucosae, intra-epithelial and intra-glandular neutrophilic infiltrate, intra-epithelial lymphocytic infiltrate ; C : diffuse metabolic gastritis

and a nodule in the epiploon. A new tumor biopsy was performed and proved not to harbor a mutation in the *braf* gene. Therefore, it was decided to start pembrolizumab. The disease was stabilized, and a complete remission was observed several months later. In May 2019 the patient presented loss of appetite and upper abdominal pain. The health status of the patient deteriorated, with anemia and hypoalbuminemia. An upper gastrointestinal endoscopy was performed showing severe gastritis with normal appearance of the oesophagus and the duodenum. Endoscopic lesions included mucosal erythema with diffuse erosions, strictly spreading between the Z line and the pylorus (Figure 1 (A,B)). Biopsies confirmed a severe atrophy of the glands, a lymphocyte-plasmocyte infiltration of the lamina propria associated with glandular, cryptic and surface epithelium destruction by neutrophils (Figure 2 (A,B)). There was no evidence of *Helicobacter pylori*.

PET scan showed clear metabolic and radiological signs of diffuse gastritis (SUV max 10,5) with hiatus hernia (Figure 2 (C)).

Immunotherapy was interrupted and a treatment with high doses of corticosteroids (methylprednisolone 32 mg PO) was initiated, with a single dose of proton pump inhibitor, leading to a rapid improvement of the symptoms. Endoscopic control performed 2 months later confirmed a complete healing of the gastric mucosa (Figure 1 (C,D)), with only signs of mild chronic antral gastritis histologically. There were also signs of reflux oesophagitis, Los Angeles grade C, as a consequence of the restauration of the secretory function of the parietal cells. PET scan control attested disappearance of gastric hypermetabolic activity.

According to the guidelines, severe auto-immune adverse events lead to withdrawal of the ICI treatment. Moreover, analysis of the KN-001 and KN-006 studies shows that the relapse rate in metastatic melanoma patients in complete remission after 2 years of pembrolizumab is less than 10% (1,2). Our patient is still in remission in January 2020.

#### Review of the literature on ICI GI toxicities

The incidence of digestive toxicity is higher with anti-CTLA-4 than with anti-PD-1, mainly manifesting as

colitis, in 8-22% of the patients (4). It usually occurs after 1-11 infusions of ipilimumab but can also start months after treatment initiation. Typical endoscopic lesions are erythema, loss of vascular pattern, vascular erosions, ulcerations. Histological analysis shows an acute inflammatory infiltrate of neutrophils and eosinophils and abscesses. This may lead to a chronic infiltration with granulomas, plasmocytosis and anomalies of the crypts (4-6).

The upper gastrointestinal tract is only rarely involved in ICI toxicity. In a study of 198 patients treated with ipilimumab, 18 patients developed gastrointestinal symptoms and underwent a endoscopic evaluation, 10 had macroscopic gastritis and 14 had histological evidence similar to that seen in the colon (5). Gastrointestinal toxicity is less frequently observed with anti -PD1, described in 1-2% of the cases, with a median time to event of 3 months(3). The most frequent symptoms are diarrhea, vomiting and abdominal pain. Endoscopy may be normal, show mild erythema or severe inflammation with four different patterns : 1. acute inflammation with neutrophils and micro-abscesses and crypts apoptosis ; 2. lymphocytic microcolitis with increased intra-epithelial lymphocytes; 3. pseudo obstruction ; 4. upper GI tract involvement (7,8). In a review of 20 symptomatic patients 4 presented with gastritis, with an histological pattern of necrosis and ulcerations with lymphocytic and neutrophilic infiltrate. Duodenal biopsies evidenced intra-epithelial lymphocytic infiltrates, partial obstructions of the villi, infiltrates of the lamina propria (9).

In an extended literature search, we additionally found 8 cases of patients with auto-immune gastritis under anti-PD1 treatment Only 4 cases followed treatment with pembrolizumab (14-17) (table 1). The clinical picture was generally composed of abdominal pain, sometimes with nausea and loss of appetite, 1 to 13 months after treatment initiation. Endoscopy was normal in one case, and ranged from diffuse erythema to hemorrhagic gastritis in the other cases. Histology showed a lymphocytic infiltrate of the lamina propria and an increase of the intra-epithelial CD8+ T lymphocytes.

High dose corticotherapy was almost always administered. The mechanism underlying this side effect is not yet fully understood but could in part be explained

Table 1. — Table summarizing reports of upper gastrointestinal tract adverse events under ICI

Ref	Patient		Treatment		Clinic	EGD <sup>c</sup>	Histologic features
	Age	Sex	ICI <sup>a</sup>	Time <sup>b</sup>			
VDP	67	F	Pembrolizumab	60 mos	loss of appetite and upper abdominal pain	Erythema and erosions of the gastric mucosae	atrophy of the glands, lymphocytic, plasmocytic infiltration of the lamina propria associated with glandular, cryptic and surface epithelium destruction by neutrophils.
(10)	44	M	Pembrolizumab	1 mo	Dyspepsia, pyrosis	Hiatal Hernia	Intra-epithelial T lymphocytes
(11)	75	M	Pembrolizumab	9 mos 13 mos <sup>d</sup>	Asymptomatic Nausea, vomiting, abdominal pain	Diffuse erythema	Lymphoplasmocytic and neutrophilic infiltration in the lamina propria, increased intra-epithelial Ly T cells CD8+>CD4+
(12)	68	F	Pembrolizumab	5 mos	Fever, anorexia, abdominal pain	Gastric erythema and erosions	Lymphocyte-predominant infiltration in the lamina propria
(13)	41	F	Pembrolizumab	7,5 mos	Epigastric pain	Hemorrhagic gastritis	Active gastritis with neutrophilic infiltrate of the lamina propria. Intra-epithelial T cell lymphocytosis CD8+>CD4+

<sup>a</sup> immune check point inhibitor (ICI) ; <sup>b</sup> time between the first dose of ICI and adverse event in months (mos) ; <sup>c</sup> oeso-gastro-duodenoscopy ; <sup>d</sup> 1<sup>st</sup> endoscopic evaluation was done because of abnormal low level uptake in the stomach wall in the Pet CT evaluation ; <sup>2</sup> 2<sup>nd</sup> endoscopic evaluation because of upper digestive tract symptoms.

by a reduction of CD4+ T regs. Clinical, endoscopic and histological patterns in the present case are consistent with those described in the literature.

Apart from its rare occurrence, the scientific interest of the current case report lies in the radiological and endoscopic documentation of pembrolizumab -induced gastritis before and under treatment by corticosteroids. Severe auto-immune inflammation was restricted to the stomach and completely resolved under therapy. In addition, the histological patterns before and after therapy are typical and the evolution under cortico-therapy confirms the auto-immune origin. Our patient had a history of several auto-immune side effects under checkpoint inhibitors, which could reflect a higher susceptibility to side effects in the upper gastrointestinal tract.

In conclusion, it is important to remember that a patient may present several auto-immune reactions under immunotherapy even after long exposure. Clinical upper gastrointestinal tract symptoms under immunotherapy, with specific endoscopic and histological appearance, is suspect of, in the absence of other causes, gastric toxicity of immunotherapy. Adequate management of these side effects leads to complete resolution and a balance between the benefit of the treatment and the side effects must be considered before reintroducing the drug. Auto-immune gastritis may be more frequently encountered in the future, considering the growing number of patients under immunotherapy.

### Conflict of interest

I declare any conflict of interest, including any financial activities, additional affiliations, personal or other relationships with other people or organizations that could influence, or be perceived to influence, their work, such as employment, consultancies, stock ownership, honoraria, patent applications/registrations, grants or other funding.

### References

- ROBERT C., RIBAS A., SCHACHTER J., ARANCE A., GROB J-J., MORTIER L., *et al.* Pembrolizumab versus ipilimumab in advanced melanoma (KEYNOTE-006): post-hoc 5-year results from an open-label, multicentre, randomised, controlled, phase 3 study. *Lancet Oncol.*, 2019, **20** : 1239-51.
- HAMID O., ROBERT C., DAUD A., HODI FS., HWU WJ., KEFFORD R., *et al.* Five-year survival outcomes for patients with advanced melanoma treated with pembrolizumab in KEYNOTE-001. *Ann. Oncol.*, 2019, **30** : 582-8.
- HAANEN JBAG., CARBONNEL F., ROBERT C., KERR KM., PETERS S., LARKIN J., *et al.* Management of toxicities from immunotherapy : ESMO Clinical Practice Guidelines for diagnosis, treatment and follow-up. *Ann. Oncol.*, 2017, **28** iv : 119-42.
- GUPTA A., DE FELICE KM., LOFTUS EV., KHANNA S. Systematic review: colitis associated with anti-CTLA-4 therapy. *Aliment. Pharmacol. Ther.*, 2015, **42** : 406-17.
- BECK KE., BLANSFIELD JA., TRAN KQ., FELDMAN AL., HUGHES MS., ROYAL RE., *et al.* Enterocolitis in Patients With Cancer After Antibody Blockade of Cytotoxic T-Lymphocyte-Associated Antigen 4. *J. Clin. Oncol.*, 2006, **24** : 2283-9.
- MARTHEY L., MATEUS C., MUSSINI C., NACHURY M., NANCEY S., GRANGE F., *et al.* Cancer Immunotherapy with Anti-CTLA-4 Monoclonal Antibodies Induces an Inflammatory Bowel Disease. *J. Crohns Colitis.*, 2016, **10** : 395-401.
- KARAMCHANDANI DM., CHETTY R. Immune checkpoint inhibitor-induced gastrointestinal and hepatic injury: pathologists' perspective. *J. Clin. Pathol.*, 2018, **71** : 665-71.
- GONZALEZ RS., SALARIA SN., BOHANNON CD., HUBER AR., FEELY MM., SHI C. PD-1 inhibitor gastroenterocolitis: case series and appraisal of "immunomodulatory gastroenterocolitis". *Histopathology*, 2017, **70** : 558-67.
- COLLINS M., MICHOT JM., DANLOS FX., MUSSINI C., SOULARUE E., MATEUS C., *et al.* Inflammatory gastrointestinal diseases associated with PD-1 blockade antibodies. *Ann. Oncol.*, 2017, **28** : 2860-5.
- YIP RHL., LEE LH., SCHAEFFER DE., HORST BA., YANG H-M. Lymphocytic gastritis induced by pembrolizumab in a patient with metastatic melanoma. *Melanoma Res.*, 2018, **28** : 645-7.
- GAFFURI P., ESPELI V., FULCINITI F., PAONE G., BERGMANN M. Immune-related acute and lymphocytic gastritis in a patient with metastatic melanoma treated with pembrolizumab immunotherapy. *Pathologica*, 2019, **111** : 92-7.
- ONUKI T., MORITA E., SAKAMOTO N., NAGAI Y., SATA M., HAGIWARA K. Severe upper gastrointestinal disorders in pembrolizumab-treated non-small cell lung cancer patient : Pembrolizumab induces upper GI disorders. *Respirol. Case Rep.*, 2018, **6** : e00334.
- RAO BB., ROBERTSON S., PHILPOTT J. Checkpoint Inhibitor-Induced Hemorrhagic Gastritis with Pembrolizumab. *Am. J. Gastroenterol.*, 2019, **114** : 196.